

VIEWPOINTS

# Vaccine-Triggered Acute Autoimmune Myocarditis: Defining, Detecting, and Managing an Apparently Novel Condition

Saidi A. Mohiddin , MBChB, MD(res); Oliver Guttman , MBBS, MD(Res); Federica Marelli-Berg , MD, PhD

**A**mong the seemingly endless “unknown-unknowns” that the COVID era has foisted on policy makers, public health, health care providers, researchers, and the public is the apparently novel cardiac disease identified in this issue of the *Journal of the American Heart Association (JAHA)*<sup>1</sup> as “myocarditis after COVID-19 vaccination,” elsewhere as “postvaccine myocarditis,” and perhaps in the future along the lines of “vaccine-triggered, self-limiting, acute autoimmune myocarditis.” This potentially serious complication has been associated with serious harm, arguably most prominently through promotion of vaccine hesitancy, another complex mechanism underlying COVID19-mediated harm.

---

## See Viewpoint by Sandeep et al.

---

A number of very different approaches will be needed to mitigate any harmful effects, including those addressing the whats, whys, and the hows of this apparently rare, currently idiosyncratic, and possibly unique phenomenon. Meanwhile, the clinician is faced with detection, monitoring, and management of affected individuals, a task further complicated by a knotty collection of significant limitations in our ability to manage myocarditis.

---

## MUTUALLY DEPENDENT LIMITATIONS: THE CATCH-22 OF MYOCARDITIS

These are well reviewed elsewhere,<sup>2</sup> and can be summarized as follows: (1) Quite distinct “types” of acute and chronic myocarditis are evident from clinical, histological, and pathogenesis perspectives; “myocarditis” is as nonspecific a diagnosis as is “hepatitis.” (2) Even when suspected, it is difficult to reliably detect and stratify myocardial inflammation into types of myocarditis in ways that are clinically relevant, accurate, cost-effective, and safe; this is particularly so when there is chronic low-grade disease. (3) We have a poorly developed understanding of root causes and effector mechanisms, features that determine prognosis and therapy (see [Moving Forward: Cutting the Knot](#)) (4) Perhaps unsurprisingly, we do not have well-evidenced therapies; providing supportive management when needed is self-evident, but apparently contradictory choices are often made between immunosuppression and antiviral agents (including immunopromoters).

Therefore, there is a Catch-22 of sorts: We are not good at detection/stratification and therefore have not developed and tested therapies for well-defined types of myocarditis; we do not have good treatments, and therefore do not routinely pursue more granular diagnoses. Notably, although cardiac magnetic resonance (CMR) imaging has transformed our ability to detect

**Key Words:** COVID-19 ■ myocarditis ■ vaccines

---

The opinions expressed in this article are not necessarily those of the editors or of the American Heart Association.

Correspondence to: Prof. Saidi A. Mohiddin, MBChB, MD(res), Barts Heart Centre, St Bartholomew’s Hospital, 1St Martin’s Le-Grand, EC1A 4EU London, UK. Email: [saidi.mohiddin@bartshealth.nhs.uk](mailto:saidi.mohiddin@bartshealth.nhs.uk)

For Disclosures, see page 5.

© 2022 The Authors. Published on behalf of the American Heart Association, Inc., by Wiley. This is an open access article under the terms of the [Creative Commons Attribution-NonCommercial-NoDerivs](#) License, which permits use and distribution in any medium, provided the original work is properly cited, the use is non-commercial and no modifications or adaptations are made.

JAHA is available at: [www.ahajournals.org/journal/jaha](http://www.ahajournals.org/journal/jaha)

acute myocardial inflammation, CMR and other imaging modalities rarely identify root causes or effector mechanisms, and have poor sensitivity for differentiating chronic progressive disease from noninflammatory cardiomyopathies.<sup>3</sup>

## MOVING FORWARD: CUTTING THE KNOT

To move beyond this impasse requires us to address the “scanty understanding of root causes and effector mechanisms” as they relate to “different types of acute and chronic” myocarditis. For example, although viral agents (most commonly viruses) are often causally implicated, there are noninfectious causes (toxins, drugs, malignancy, autoimmunity, RNA vaccines, etc.) as well as nonviral microbial causes. Human and animal studies supply substantial evidence that, in susceptible hosts, acute and/or chronic heart-specific autoimmunity can be triggered by self-limiting viral infections.<sup>4</sup> Infection is not necessary for this, however: heart-specific autoimmunity can develop when myocardial antigens are presented to the immune system in an appropriate place and inflammatory context (eg, inoculation of susceptible mouse strains with myosin heavy chain plus vaccine adjuvant). This gives rise to an intriguing hypothesis that other causes of acute, chronic, or recurrent myocardial injury can promote cardiac autoimmunity in susceptible individuals via similar mechanisms.<sup>5</sup>

To illustrate how distinct inflammatory mechanisms could co-exist, interact, and why they can be difficult to separate out, it may help to consider what we know of myocardial inflammation caused by or following COVID-19 infections. Data suggest that forms of myocarditis can result from the following: myocellular lysis from replicating virions; myocardial injury secondary to systemic hyperinflation; adaptive immune responses targeting infected cells (lymphocytic infiltrates are typical here); and postinfectious Multi-System Inflammatory Syndrome.<sup>6–8</sup>

To belabor the point: in otherwise apparently similar clinical presentations of myocarditis, myocardial biopsy may detect evidence of viral infection, but frequently fails to do so. Histology commonly identifies CD3+ lymphocytes, but eosinophilic, granulomatous, giant-cell, and mixed infiltrates are detected in others cases of “myocarditis,” each of which is associated with different outcomes.<sup>2,9</sup> Humoral responses to virus and/or self may also be important, resulting in antibody-mediated myocardial injury as well as effects resulting from agonist/antagonist activity if/when receptor epitopes are targeted.<sup>2</sup>

These diversions, which seek to emphasize heterogeneity in cause and effect, have meaningful clinical

implications; in developing strategies to suppress persistent inflammation, a mechanistic “dichotomy” (between immunologically mediated myocardial injury that targets viral antigen on chronically infected heart cells, and immunologically mediated myocardial injury directed against self-antigens) is of key importance. Notably, as suggested below, this dichotomy alongside the other limitations described above, are considerably less relevant when considering postvaccine myocarditis from a purely clinical perspective.

## DETECTION, DEFINING, AND MANAGEMENT OF POSTVACCINE MYOCARDITIS

Sandeep et al.<sup>1</sup> adopt a pragmatic approach to the detection and management of postvaccine myocarditis in children and adolescents. Their approach can be considered a 3-part pathway.

First, the approach to detection and diagnosis assesses the probability that a presentation with acute myocardial injury is causally related to recent vaccination. Diagnosis is considerably more straightforward than in other settings where myocarditis might be suspected, because most presentations currently confer a high pretest probability.

A unique combination of typical features currently characterizes the vast majority of cases of postvaccine myocarditis: near identical, easily “detected” pathogenetic agents; typical temporal features; and similar clinical features typically including chest pain, ECG changes, and troponin elevation. Clinical presentations share yet other strikingly similar features, including sex (overwhelmingly male), young age (more clearly defined when adult cases are studied), when vaccine exposure occurred (within 5 days of a second mRNA vaccine is typical; intriguingly, some data infer that presentations after the first dose can develop if infection with COVID-19 acts as the first “vaccine”<sup>10</sup>), and medium-term outcomes appear to be overwhelmingly benign.<sup>10–15</sup>

Considering and eliminating alternative causes of acute myocardial injury also receive due attention in this part of the pathway; these alternative causes include other forms of myocarditis. In fact, postvaccine myocarditis strongly resembles a form of acute myocarditis that commonly presents on acute coronary syndrome pathways with cardiac symptoms (usually cardiac chest pain), ECG abnormalities, troponin elevation, and unobstructed arteries.<sup>16</sup> Often referred to as “acute coronary syndrome–like” myocarditis, presentations often follow on the heels of symptoms of a mild resolving/resolved viral infection, and young male adults form the majority of patients; it must be asked whether both phenomena are similar forms of “triggered, self-limiting, acute autoimmune myocarditis.”

Although “acute coronary syndrome–like” myocarditis presentations include risks of short-term arrhythmic/heart failure events, myocardial recovery and long-term prognosis appear to be excellent—particularly if other rare conditions with similar presentations are identified and excluded (see below). This appears to be another similarity with postvaccine myocarditis.

The second part of the pathway aims to identify cases at risk of arrhythmic/heart failure events in postvaccine myocarditis. Detecting markers that indicate or predict severe contractile impairment, heart block, or ventricular tachyarrhythmia form the basis for the pathway’s monitoring component. Although these features are not validated for use in this form of myocarditis, it seems eminently reasonable to equate evidence of relentless myocardial injury, progressive conduction delay, and ventricular irritability with risks of a poor outcome, regardless of the disease process. Do these events occur in postvaccine myocarditis?

Overwhelmingly, available data indicate mild, self-limited clinical disease with clinical and imaging data suggesting fairly complete resolution in most. Reviewing the literature is to be done with caution: the many published case reports and series inevitably include reporting bias, and the several systematic reviews<sup>10–13</sup> draw from the same pool of published cases, creating a sort of repetition bias. Other sources include safety surveillance,<sup>14,17</sup> insurance claims,<sup>18</sup> and national registry databases; these are also likely to underreport milder cases, and a truer disease representation will likely include greater incidence with lower severity. Nonetheless, the consistency of clinical features, across these different data sources, is striking; typically, ≈90% are male, with a median age somewhere in the 20s (depending on age groups vaccinated). Serious complications including cardiogenic shock and death are reported, though these appear rare and subject to both reporting and repetition bias.

Regardless, an approach like that described by Sandeep and colleagues would almost certainly have identified most of the complicated (adult) cases summarized in one of the systematic reviews.<sup>13</sup> Given the apparent low risk of the condition, however, future iterations of such pathways are likely to include higher thresholds for admission, lower thresholds for discharge, and additional diagnostic work-ups when myocardial injury is severe or relentless. In our Institute’s pathway for suspected myocarditis in adults, early CMR (sometimes repeated days later in aggressive disease) has a prominent role in diagnosis as well as prognosis.<sup>16</sup> This approach, as well as considering endomyocardial biopsy and positron emission tomography with <sup>18</sup>fluorodeoxyglucose before immunosuppression, are other areas where these pathways may be further shaped for the purposes of risk assessment.

The third component recommends that immunosuppression should be considered alongside supportive management only when adverse outcomes seem likely or have been manifest. By and large, this assessment is accomplished by considering the magnitude of myocardial injury, its functional consequences, and the likely trajectory of the injurious process.

If the diagnosis of postvaccine myocarditis is correct, it seems safe to assume that the effector mechanism includes immunologically mediated myocardial injury. Accordingly, there is support for immune suppression, at the same time eliminating concerns of causing harm by “releasing” an undetected infectious cause from its immunological constraints. On the face of it, this is a very real and clinically relevant difference between managing this form of myocarditis and most presentations of myocarditis where pathogenesis is less immediately apparent. Indeed, many of the case reports document the use of apparently uncomplicated immunosuppression regimens, most commonly with glucocorticoids and/or intravenous immunoglobulin.

Another word of caution may be necessary here too: Of the few adult deaths reported in detail,<sup>13</sup> several have clinical features that do not align with the stereotypical profile (eg, older, female, and >7 days after vaccination). For these cases, we must ask whether the diagnosis is incorrect, and/or if postvaccine “immunological turbulence” has triggered another, perhaps quiescent, inflammatory process that requires more aggressive or more prolonged immunosuppression, or perhaps very different types of therapy. From this perspective, CMR, positron emission tomography with <sup>18</sup>fluorodeoxyglucose, and endomyocardial biopsy may be even more important.

## POSTVACCINE MYOCARDITIS IN ADULTS: LOWER SIGNAL, MORE NOISE

An approach to detection and management in adults that includes the same components described above appears to be appropriate, but with the important difference that pretest probabilities change in older age groups. The incidence of postvaccine myocarditis becomes much lower, and alternative causes of cardiac symptoms and acute myocardial injury are more frequently encountered, even in populations with normal coronary angiograms.<sup>16</sup> Accordingly, our own in-house pathways for evaluating adult patients will almost always include early CMR to help sort through a list of differential diagnoses, and endomyocardial biopsy when immunosuppression is being considered to suppress immune-mediated myocardial injury. Positron emission tomography with <sup>18</sup>fluorodeoxyglucose imaging and

genetic testing may also play an important part in these assessments.<sup>19</sup>

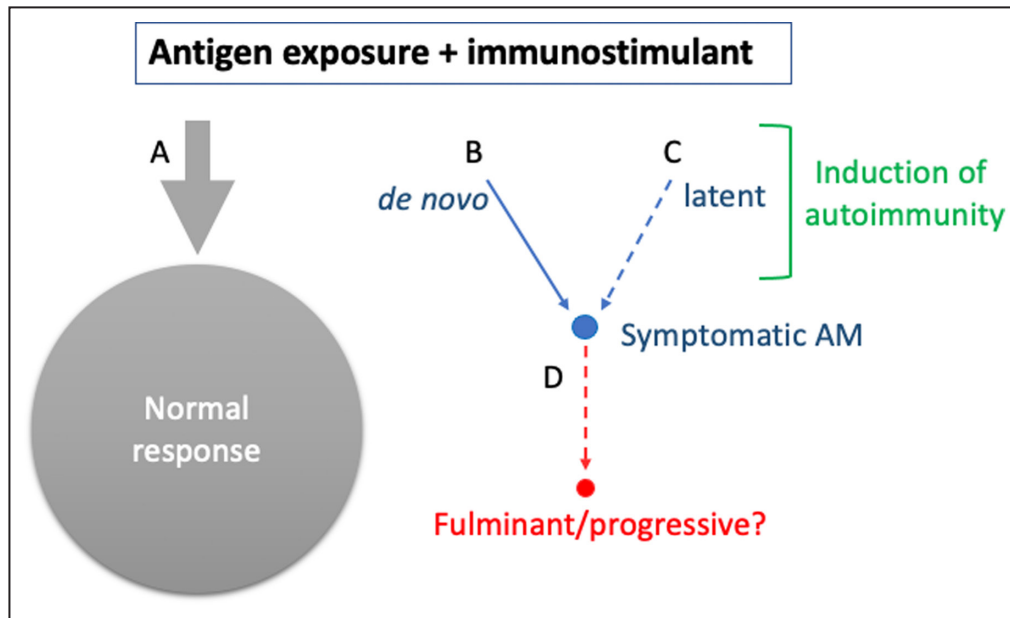
### LIMITATIONS OF THE PROPOSED PATHWAY(S): NO PLAN SURVIVES CONTACT WITH THE ENEMY

Sandeep et al are to be congratulated for putting together a clearly thought-out and pragmatic pathway, one that can readily be iterated to accommodate advances in understanding of this disease, and can be adapted for use in older populations. As suggested above, pediatric pathways may become increasingly similar to schemes for adult disease, as immunity, immunization, and COVID-19 exposure risk all drift towards defining a lower signal/higher noise equilibrium that includes fewer admissions with lower pretest probabilities. One critical comment: in our view, the convention to conflate myocarditis with pericarditis is problematic and should be avoided; myocardial injury sits at the center of the issue, and the outcomes of concern are those common to acute myocardial syndromes and not to pericardial disease.

Otherwise, new questions and practical issues (eg, should older or female patients be managed differently, role for CMR, positron emission tomography with <sup>18</sup>fluorodeoxyglucose and endomyocardial biopsy, how long to give immunosuppression and what is best, who should/should not have follow up and when) will become apparent in utilization, and when translated into lower resource settings and the referral centers where complex cases should be managed and prospectively studied.

### MYOCARDIAL INFLAMMATION AND COVID/VACCINE: THE SILVER LINING

The COVID era has already forced a wider audience to pay closer attention to the range of hazards resulting from consequences of "maladaptive" inflammatory responses, including the triggering of organ-specific autoimmune disorders in susceptible individuals. With regard to myocardial inflammation, standout lessons include the following: (1) that the same causal agent can initiate quite different types of myocarditis, mediated by distinct immunopathological mechanisms; and (2) that for some of these types of myocarditis, the



**Figure. Myocarditis Is a Rare Complication Following Vaccination: A Graphic Summary.**

The overwhelming proportion of exposed individuals mount normal immune responses and do not develop myocardial inflammation. In a very small fraction of previously healthy susceptible hosts, antigen and/or immunostimulation trigger self-limiting immune-mediated myocardial injury. The mechanisms underlying this maladaptive immune response, and how they relate to acquired/innate host characteristics and/or to antigen/immunostimulant factors, are largely unknown. It is hypothesized that some individuals with prior myocardial injury may have latent adaptive immunological memory for cardiac self-antigen(s) and may be at greater risk of myocarditis when exposed to these or similar triggers. In such cases, acquired host characteristics may be of central importance in determining outcomes. A small number of individuals with postvaccine myocarditis may progress on a more fulminant acute course, or develop chronic myocarditis. Detecting these cases, with a view to therapeutic intervention, is the ultimate purpose of the proposed clinical approach. AM indicates acute myocarditis.

trigger may be the antigen (alongside immunological co-stimulation) rather than an infectious agent per se. It also seems likely that immunizing therapies other than mRNA vaccines can trigger myocardial inflammation when given to susceptible populations; perhaps notably, the myocarditis following smallpox vaccination also appears to favor young male subjects.<sup>20</sup>

A more comprehensive understanding of initiators, immunological effector mechanisms, and classifications of myocarditis is likely to result, and an improved ability to detect and manage inflammatory heart muscle disease should surely follow. A graphic summary of this viewpoint can be seen in the [Figure](#).

## ARTICLE INFORMATION

Received June 21, 2022; accepted August 15, 2022.

### Affiliations

Barts Health NHS Trust, London, UK (S.A.M., O.G.); Barts and the London School of Medicine and Dentistry, Queen Mary University of London, London, UK (S.A.M., F.M.); and Institute of Cardiovascular Science, University College London, London, UK (O.G.).

### Disclosures

None.

## REFERENCES

- Sandeep N, Fairchok MP, Hasbani K. Myocarditis after COVID-19 vaccination in pediatrics: A proposed pathway for triage and treatment. *J Am Heart Assoc*. 2022;11:e026097. doi: 10.1161/JAHA.121.026097
- Tschope C, Ammirati E, Bozkurt B, Caforio ALP, Cooper LT, Felix SB, Hare JM, Heidecker B, Heymans S, Hubner N, et al. Myocarditis and inflammatory cardiomyopathy: Current evidence and future directions. *Nat Rev Cardiol*. 2021;18:169–193. doi: 10.1038/s41569-020-00435-x
- Ismail TF, Hua A, Plein S, D’Cruz DP, Fernando MMA, Friedrich MG, Zellweger MJ, Giorgetti A, Caobelli F, Haaf P. The role of cardiovascular magnetic resonance in the evaluation of acute myocarditis and inflammatory cardiomyopathies in clinical practice – a comprehensive review. *Eur Heart J Cardiovasc Imaging*. 2022;23:450–464. doi: 10.1093/ehjci/jeac021
- Muller AM, Fischer A, Katus HA, Kaya Z. Mouse models of autoimmune diseases - autoimmune myocarditis. *Curr Pharm Des*. 2015;21:2498–2512. doi: 10.2174/1381612821666150316123711
- Eriksson U, Ricci R, Hunziker L, Kurrer MO, Oudit GY, Watts TH, Sonderegger I, Bachmaier K, Kopf M, Penninger JM. Dendritic cell-induced autoimmune heart failure requires cooperation between adaptive and innate immunity. *Nat Med*. 2003;9:1484–1490. doi: 10.1038/nm960
- Guzik TJ, Mohiddin SA, Dimarco A, Patel V, Savvatis K, Marelli-Berg FM, Madhur MS, Tomaszewski M, Maffia P, D’Acquisto F, et al. COVID-19 and the cardiovascular system: Implications for risk assessment, diagnosis, and treatment options. *Cardiovasc Res*. 2020;116:1666–1687. doi: 10.1093/cvr/cvaa106
- Siripanthong B, Asatryan B, Hanff TC, Chatha SR, Khanji MY, Ricci F, Muser D, Ferrari VA, Nazarian S, Santangeli P, et al. The pathogenesis and long-term consequences of COVID-19 cardiac injury. *J Am Coll Cardiol Basic Trans Science*. 2022;7:294–308. doi: 10.1016/j.jacbs.2021.10.011
- Bajaj R, Sinclair HC, Patel K, Low B, Pericao A, Manisty C, Guttmann O, Zemrak F, Miller O, Longhi P, et al. Delayed-onset myocarditis following COVID-19. *Lancet Respir Med*. 2021;9:e32–e34. doi: 10.1016/S2213-2600(21)00085-0
- Cooper LT, Baughman KL, Feldman AM, Frustaci A, Jessup M, Kuhl U, Levine GN, Narula J, Starling RC, Towbin J, et al. The role of endomyocardial biopsy in the management of cardiovascular disease: A scientific statement from the American Heart Association, the American College of Cardiology, and the European Society of Cardiology. *Circulation*. 2007;116:2216–2233. doi: 10.1161/CIRCULATIONAHA.107.186093
- Lee ASY, Balakrishnan IDD, Khoo CY, Ng CT, Loh JXK, Chan LL, Teo LLY, Sim DKL. Myocarditis following COVID-19 vaccination: A systematic review (October 2020–October 2021). *Heart Lung Circ*. 2022;31:757–765. doi: 10.1016/j.hlc.2022.02.002
- Park DY, An S, Kaur A, Malhotra S, Vij A. Myocarditis after COVID-19 mRNA vaccination: A systematic review of case reports and case series. *Clin Cardiol*. 2022;45:691–700. doi: 10.1002/clc.23828
- Goyal M, Ray I, Mascarenhas D, Kunal S, Sachdeva RA, Ish P. Myocarditis post SARS-CoV-2 vaccination: A systematic review. *QJM*. 2022;hcac064. doi: 10.1093/qjmed/hcac064
- Ilonze OJ, Guglin ME. Myocarditis following COVID-19 vaccination in adolescents and adults: A cumulative experience of 2021. *Heart Fail Rev*. 2022;1–11. doi: 10.1007/s10741-022-10243-9
- Oster ME, Shay DK, Su JR, Gee J, Creech CB, Broder KR, Edwards K, Soslow JH, Dendy JM, Schlaudecker E, et al. Myocarditis cases reported after mRNA-based COVID-19 vaccination in the US from December 2020 to August 2021. *JAMA*. 2022;327:331–340. doi: 10.1001/jama.2021.24110
- Truong DT, Dionne A, Muniz JC, McHugh KE, Portman MA, Lambert LM, Thacker D, Elias MD, Li JS, Toro-Salazar OH, et al. Clinically suspected myocarditis temporally related to COVID-19 vaccination in adolescents and young adults: Suspected myocarditis after COVID-19 vaccination. *Circulation*. 2022;145:345–356. doi: 10.1161/CIRCULATIONAHA.121.056583
- Gallagher S, Jones DA, Anand V, Mohiddin S. Diagnosis and management of patients with acute cardiac symptoms, troponin elevation and culprit-free angiograms. *Heart*. 2012;98:974–981. doi: 10.1136/heartjnl-2011-301121
- Straus W, Urdaneta V, Esposito DB, Mansi JA, Rodriguez CS, Burton P, Vega JM. Analysis of myocarditis among 252 million mRNA-1273 recipients worldwide. *Clin Infect Dis*. 2022;ciac446. doi: 10.1093/cid/ciac446
- Wong HL, Hu M, Zhou CK, Lloyd PC, Amend KL, Beachler DC, Secora A, McMahon-Walraven CN, Lu Y, Wu Y, et al. Risk of myocarditis and pericarditis after the COVID-19 mRNA vaccination in the USA: A cohort study in claims databases. *Lancet*. 2022;399:2191–2199. doi: 10.1016/S0140-6736(22)00791-7
- Enrico Ammirati FR, Piriou N, Infirri LS, Mohiddin SA, Mazzanti A, Shenoy C, Cavallari UA, Imazio M, Aquaro GD et al. Acute myocarditis associated with Desmosomal gene variants. *J Am Coll Cardiol HF*. In Print
- Parmar K, Subramanyam S, Del Rio-Pertuz G, Sethi P, Argueta-Sosa E. Cardiac adverse events after vaccination—a systematic review. *Vaccines (Basel)*. 2022;10:700. doi: 10.3390/vaccines10050700